


Anatomical Variations of Origin of Femoral Nerve- A Cross-sectional Observational Study

BJ ARCHANA¹, AMAR LAKSHMAN SINGH², K PRIYANKA³, PRABHAKAR PRADEEP⁴, KR ASHA⁵

ABSTRACT

Introduction: Femoral nerve is an important nerve supplying the lower limb. Variations in the origin and course of femoral nerve are frequently encountered. The knowledge of these is of vital importance for orthopaedic surgeons and anaesthetists to prevent iatrogenic injury and debilitating postoperative complications.

Aim: To document the variations in origin and course of femoral nerve and its clinical significance.

Materials and Methods: A cross-sectional study was conducted on 50 specimens by dissecting 25 embalmed adult human cadavers of South Indian population out of which 20 were male and five were female cadavers. The study was conducted by dissection method done in the Department of Anatomy in Sri Siddhartha Medical College, Tumkur and Sri Siddhartha Institute

of Medical Sciences and Research Centre, T Begur, Bangalore Rural, Karnataka, India. Results were expressed in terms of frequency and percentages.

Results: Out of the 50 specimens, in 47 specimens femoral nerve was found to be originating normally from dorsal divisions of L2, L3, L4 spinal nerves, whereas in three specimens it was found to be originating from dorsal divisions of L1, L2, L3. In two specimens femoral nerve was seen emerging from behind the psoas major muscle.

Conclusion: A good knowledge about the embryological basis and variations in the branching pattern of femoral nerve is essential because of its numerous clinical implications, especially in localising neurological lesions of nerves, for their early and accurate diagnosis and thus preventing iatrogenic anaesthetic complications.

Keywords: Entrapment neuropathy, Nerve block, Prefixed lumbar plexus, Psoas abscess, Psoas block, Spinal anaesthesia

INTRODUCTION

The femoral nerve arises from the dorsal divisions of the second to fourth lumbar ventral rami. It is the largest branch of lumbar plexus. Femoral nerve emerges low on the lateral border of psoas major muscle. It traverses to the thigh, passing behind iliac fascia posterior to the inguinal ligament. In its abdominal course, it provides muscular branches to iliacus and pectineus and vascular branches to femoral artery which may occasionally arise from thigh [1].

The femoral nerve enters the thigh by running down outside the femoral sheath, behind the fascia iliaca and enters the thigh lateral to the femoral artery behind the inguinal ligament. About 4 cm below the inguinal ligament, it ends by dividing into anterior and posterior divisions. The anterior division gives off three branches namely-intermediate and medial femoral cutaneous nerves and nerve to sartorius. The posterior division gives off the nerve to quadriceps femoris and the saphenous nerve [2-4].

Frequent variations are encountered in the branches of lumbar plexus. Vertebral anomalies have been implicated to cause the plexus to arise in a post fixed form [5,6].

Lumbar plexus blocks produce anaesthesia of most of the lumbar nerve roots and some of the sacral nerve roots. It therefore produces anaesthesia to the lower extremity in the distribution of the femoral nerve, the obturator nerve and the lateral cutaneous nerve of the thigh. This block is mainly indicated for the management of pain associated with unilateral lower limb surgery [7].

Femoral nerve block is usually performed just below the inguinal ligament on the main trunk of the femoral nerve. Femoral nerve block can be incomplete if there is higher division of the femoral nerve in iliac fossa [8]. Pectineus muscle is supplied from its ventral surface by the nerve to pectineus, which emerges posterior to the femoral sheath, lying medial to the femoral nerve, this assumes morphological importance than clinical. Lateral cutaneous nerve of

thigh usually arises from dorsal divisions of L2 and L3 and if it arises from the femoral nerve, it may create confusion in the process of treatment of meralgia paraesthetica [3].

Variations are principally due to the variable genetic composition. Genetic factors are implicated to be the major cause of these variations. These neuromuscular variations are due to the errors of embryological development [9-12].

The present study aims at dissecting, identifying and recording the variations in the origin of the femoral nerve from its root.

MATERIALS AND METHODS

The present study was a cross-sectional observational study which was conducted on 50 specimens by dissecting 25 embalmed adult human cadavers of South Indian population, out of which 20 were male and five were female cadavers.

This study was conducted in the Department of Anatomy in Sri Siddhartha Medical College, Tumkur (19 cadavers) during (August 2014-July 2018) and during 2019-20 in 6 cadavers at Sri Siddhartha Institute of Medical Sciences and Research Centre, T-Begur, Bangalore Rural, Karnataka, India. The standard procedure was followed for dissection [13].

Inclusion criteria: Cadavers in which anterior abdominal wall and abdominal viscera had been studied and removed with undisturbed posterior abdominal wall structures were selected for the study. Cadavers with intact 12th thoracic, 5 lumbar vertebrae, sacrum, psoas major, quadratus lumborum, transversus abdominis, and iliacus muscle were included in the study.

Exclusion criteria: Specimens with any abnormality or pathology in this region disturbing the nerve anatomy were excluded from the study.

The posterior abdominal wall was visualised and the structures namely 12th rib, psoas major, quadratus lumborum, transversus abdominis, iliacus muscles and their covering fascia were identified.

The muscles were exposed by removing their fascial covering. Injury to the nerves related to the muscles was avoided. The psoas major muscle was traced through its whole length in the abdomen.

- The femoral nerve emerging from lateral border of the muscle was exposed, identified and cleaned.
- Variations, if any in the emergence of the nerve from borders and surfaces of the psoas muscle were distinguished. The sample was numbered and photographed documenting the emergence of nerve from the psoas muscle. The psoas muscle was then removed by piecemeal from the transverse processes of the lumbar vertebrae and intervertebral discs, disentangling the ventral rami of the lumbar nerves from its substance thus exposing the plexus and its branches.
- The vertebrae were identified by articulation of 12th rib with 12th thoracic vertebra and also by identification of lumbosacral joint between 5th lumbar vertebra and sacrum. Roots were identified emerging from corresponding intervertebral foramina.
- Formation of femoral nerve was observed. Variations were taken note of. Branches were identified and traced till their exit from pelvic cavity. Variations, if any in the branching pattern was made note of.
- Any accessory nerves arising from lumbar plexus were also noted. Each specimen was photographed individually after dissection.

STATISTICAL ANALYSIS

Results were expressed in terms of frequency and percentages as it was an observational study.

RESULTS

Out of the 50 specimens, in three specimens it was found to be originating from dorsal divisions of L1, L2, L3. In all the three specimens, the variation was seen on the right side only [Table/Fig-1], two in males [Table/Fig-2-3] and one in female cadaver [Table/Fig-4]. In rest of the 47 specimens, femoral nerve was found to be arising from the dorsal divisions of ventral rami of L2, L3, L4 spinal nerves [Table/Fig-5]. In two specimen femoral nerve was noted passing behind the psoas major muscle, after its piecemeal removal [Table/Fig-6].

Total number of cases in males			Total number of cases in females		
Total male cadavers	Variations seen on right side	Variations seen on left side	Total female cadavers	Variations seen on right side	Variations seen on left side
20	02	Nil	05	01	Nil

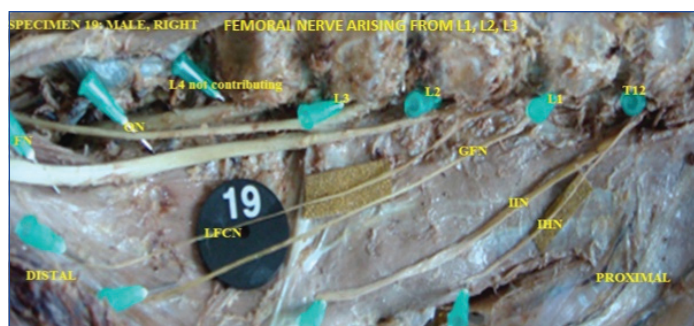
[Table/Fig-1]: Sex and side incidence of variations in femoral nerve.



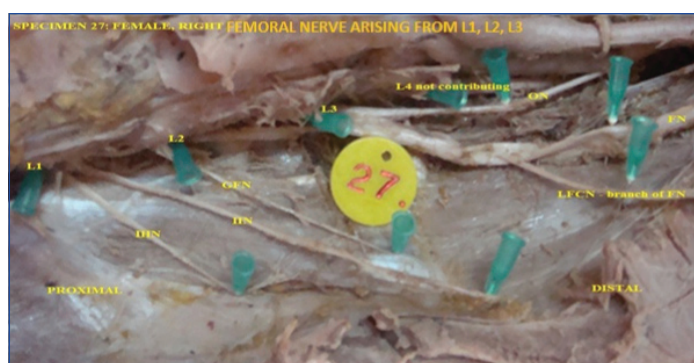
[Table/Fig-2]: Origin of femoral nerve from dorsal divisions of ventral rami of L1, L2, L3 in male cadaver on the right side.
*T12: Twelfth thoracic ventral rami; L1, L2, L3, L4: 1st, 2nd, 3rd and 4th Lumbar ventral rami; FN: Femoral nerve; ON: Obturator nerve

DISCUSSION

Lumbosacral region in man has a special significance both in evolution and clinical aspect because of his erect posture. Lumbar spine plays an important role in weight transmission and distribution in standing posture and for this reason; lumbar disc herniations are more common due to the stress and greatest motion they are



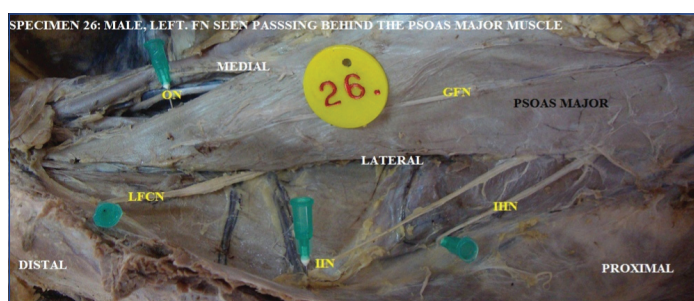
[Table/Fig-3]: Origin of femoral nerve from dorsal divisions of ventral rami of L1, L2, L3 in male cadaver on the right side.
*T12: Twelfth thoracic ventral rami; L1, L2, L3: 1st, 2nd, 3rd; FN: Femoral nerve; ON: Obturator nerve; GFN: Genitofemoral nerve; IIN: Ilioinguinal nerve; IHN: Iliohypogastric nerve



[Table/Fig-4]: Origin of femoral nerve from dorsal divisions of ventral rami of L1, L2, L3 in female cadaver on the right side.
L1, L2, L3: 1st, 2nd, 3rd; FN: Femoral nerve; ON: Obturator nerve; GFN: Genitofemoral nerve; LFCN: Lateral femoral cutaneous nerve; IIN: Ilioinguinal nerve; IHN: Iliohypogastric nerve



[Table/Fig-5]: Origin of femoral nerve from dorsal divisions of ventral rami of L2, L3, L4 in male cadaver on the left side.
*T12: Twelfth thoracic ventral rami; L1, L2, L3, L4: 1st, 2nd, 3rd and 4th Lumbar ventral rami; FN: Femoral nerve; ON: Obturator nerve; GFN: Genitofemoral nerve; LFCN: Lateral femoral cutaneous nerve; IIN: Ilioinguinal nerve; IHN: Iliohypogastric nerve



[Table/Fig-6]: Femoral nerve was observed to be passing behind the psoas major muscle deviating from its normal course of emerging from low lateral border of the muscle.
ON: Obturator nerve; GFN: Genitofemoral nerve; LFCN: Lateral femoral cutaneous nerve; IIN: Ilioinguinal nerve; IHN: Iliohypogastric nerve

subjected to [14]. Disc prolapse is a cost which a man has to pay for standing on his legs. Lumbar plexus and its branches play an important role in regional anaesthesia, Nerve blockade is commonly used to alleviate pain in oncosurgeries of sacroiliac and pelvic region [15]. The knowledge of topographical features and variations

of branches of lumbar plexus is important in spinal anaesthesia, spinal operations in spondylosurgery, endoscopic operations in retroperitoneal approach in laser discectomy, ozonotherapy etc., [16].

Lumbar plexus is classified as prefixed, as the femoral nerve receives contribution from 1st lumbar nerve in 60% of cases [17]. The femoral nerve is formed by the union of the anterior rami of the 2nd, 3rd and 4th lumbar spinal nerves. On the right side, in three male specimens the lumbar plexus was prefixed. The femoral nerve is formed by the branch from the 1st, 2nd, and 3rd lumbar spinal nerves.

Matejck V has stated that neural roots in a prefixed plexus receive more filaments from above located spinal nerves. This explains the injuries of prefixed plexus resulting in more pronounced peripheral lesions than the post fixed variety [16].

Astik RB et al., reported abnormally long L2 root on both sides in a male cadaver. On the right side, it was 92 mm long. After emerging from intervertebral foramen between L2 and L3 vertebrae, it divided into ventral and dorsal division. The ventral division fused with ventral division of L3 and L4 roots to form obturator nerve, and the dorsal division of L2 descended in iliac fossa and fused with combined dorsal division of L3 and L4 to form the femoral nerve, 35 mm above the inguinal ligament on right side. On the left side L2 root was 85 mm long, had the same course as on the right side, and it fused with combined dorsal division of L3 and L4 to form the femoral nerve, 42 mm above the inguinal ligament [18].

Bardeen CR and Elting AW reported femoral nerve arising from L2, L3, L4 in 50.61%, L1, L2, L3 in (13.82%), L3, L4, in 19.9%, L3, L4, L5 in 4.06% [17]. Bergman RA et al., reported that femoral nerve usually arises from L1, L2, L3, L4. It may arise in high form, from T12, L1, L2, L3, L4 or low form from L1, L2, L3, L4, L5 [19]. In the present study, out of the 50 specimens, femoral nerve was seen to be originating from the dorsal divisions of ventral rami of L1, L2, L3 spinal nerves in three specimens (6% of cases). Variations were encountered only on the right side in two male and one female cadavers. In rest of the 47 specimens (94% of cases), femoral nerve was found to be arising from the dorsal divisions of ventral rami of L2, L3, L4 spinal nerves.

Iliac fascia forms a covering over the femoral nerve. Psoas and iliacus muscles are also roofed over by the same which makes it a predisposing factor for femoral neuropathy due to haematoma or abscess formed in these muscles following anticoagulant therapy, vessel catheterization or psoas abscess [20,21].

Sharrock N has reported cases of femoral nerve blockade in procedures involving lateral femoral nerve blocks. This may be explained on basis of anatomical variations with lateral femoral cutaneous nerve emerging as a branch of femoral nerve. Hence, these variations need to be borne in mind when performing nerve blocks of either nerves to prevent discomforting postoperative symptoms like numbness [22].

Femoral nerve block can be used to provide anaesthesia for the anterior thigh, knee and a small part of the medial foot. It is typically used in conjunction with other lower extremity blocks. It may also be used for postoperative pain relief following knee surgery [23].

Degenerative disc disease, spondylolisthesis, and scoliotic or kyphotic deformity can be treated by the minimally invasive lateral transpsoas approach to the lumbar spine. Due to the location of the branches of lumbosacral plexus within the psoas muscle, the risk of motor and sensory nerve injury is present when traversing the lumbosacral plexus with the dilator or during retractor positioning over the disc space. Iatrogenic operative injury and postoperative complications can be avoided by a sound knowledge of the relevant regional anatomy [24].

Cardosi RJ et al., conducted a study on 1210 patients undergoing major pelvic surgery to estimate the incidence, aetiology and outcome of neuropathies. They reported that 23 of 1210 patients

undergoing surgery suffered a postoperative neuropathy for an incidence of 1.9%. Neurologic injury involved the obturator (n=9), ilioinguinal/iliohypogastric (n=5), genitofemoral (n=4), femoral (n=3) nerves. Aetiologies were as a result of direct surgical trauma, stretch injury, suture entrapment or were retractor related [25].

The femoral nerve injury has a wide range of aetiology from intra pelvic injury due to large-blade, self-retaining retractors used during pelvic operations to injury in the inguinal region due to gunshots, knife wounds, glass shards, or needle puncture in some medical procedures. Diabetic amyotrophy is the most common cause of femoral nerve neuropathy. Traumatic injuries in femoral triangle usually involve the femoral artery, but the femoral nerve can be injured if it is inadvertently sutured during repair of this artery [26].

Moore AE and Stringer MD conducted a systematic review of iatrogenic femoral nerve injuries between 2000 and 2010. They reported that iatrogenic femoral nerve injury can occur as a complication of common abdominal, pelvic and orthopaedic operations and after femoral nerve blocks and femoral artery puncture. Mechanism of injury includes direct trauma and ischemia from retraction or stretching the nerve [27].

Al Ajmi A et al., reported two cases of femoral neuropathy related to lithotomy positioning and self-retaining retractor use. They concluded that iatrogenic femoral neuropathy is a complication resulting from compression, stretch, ischemia or direct trauma of nerve during hip arthroplasty, self-retaining retractor use in pelvico-abdominal surgery, lithotomy positioning for anaesthesia or labour [28].

Dillavou ED et al., reported an incidence of 0.17% of femoral neuropathies due to compression by self-retaining retractors during intra-abdominal surgeries [29].

Orthopaedic and plastic surgeons perform the femoral nerve block for providing anaesthesia to anterior and lateral aspects of the thigh. The femoral nerve might be offended by suture or staples, tissue scar entrapment, local anaesthesia blockade or direct compression [30].

In present study, femoral nerve was seen emerging from lower lateral border of the muscle in 48 cases, except in two cases where it was emerging undercover of the psoas major muscle. This is of clinical importance as the nerve trunk is more likely to get compressed in psoas muscle abscess, traumatic haematoma from sports injuries or vehicular accidents, and blood dyscrasias like haemophilia leading to bleeding diathesis. The main trunk of femoral nerve may be compressed by retroperitoneal tumours or retroperitoneal haemorrhage in patients on anticoagulants or with a bleeding diathesis and in diabetes mellitus [31].

Femoral nerve roots emerging from the intervertebral foramina are exposed to higher risk of injury due to their regional disposition. Their placement in close relation to abdominopelvic organs like psoas major muscle, caecum, appendix, colon, ovaries, ureter and iliac bone make them vulnerable to be involved in pathologies of these organs.

Surgical causes like psoas muscle abscess, iliac haematomas, retroperitoneal tumours, medical causes like diabetes, obesity, pregnancy, traumatic causes like unstable vertical fracture of pelvis and radiation induced plexopathy form a few of the wide spectrum of pathologies affecting the femoral nerve.

Surgical and anaesthetic interventions in this region for a variety of causes predisposes to injuries of the plexus. This results in several discomforting and sometimes debilitating clinical conditions like meralgia paraesthetica, groin pain, testicular pain and limb weakness. This not only affects the early recovery of a patient post-surgery, but also causes physical disability. This bears an impact on everyday tasks and prospects of employment with subsequent derangement in the socio-economic condition of an individual.

Embryological basis: Deviations in lumbosacral plexus formation are caused by a deviation from normal development process, during the fourth week of foetal development [16].

Variations in anatomical structure have an embryological basis. Plexuses supplying the limbs are formed when somatic branches of spinal nerves stream out into the developing limb buds by passing below the ends of myotomes. They then differentiate into definitive trunks- anterior and posterior, proceeding to the ventral and dorsal surfaces of limb buds respectively. There is also union taking place between trunks of two different spinal nerves.

An abnormal union between two spinal nerves or its trunks usually accounts for the variations encountered. These intrauterine abnormalities result in compensatory variations between adjacent nerves explaining origin of lateral femoral cutaneous nerve from femoral nerve and splitting of femoral nerve by psoas major muscle [32].

Limitation(s)

Limitation of present study was the course of the nerve was studied only till its exit from the pelvic brim. Magnetic Resonance Imaging (MRI) study of lumbar nerve roots and inclusion of branching pattern of the femoral nerve in the thigh may contribute to better understanding of clinical implications of its variations in its origin.

CONCLUSION(S)

The knowledge of origin variability of the femoral nerve is essential for medical fraternity to steer clear from iatrogenic injury to femoral nerve during regional nerve blocks and in treatment of conditions like psoas abscess and meralgia paraesthetica.

Acknowledgement

I wish to thank Dr. Lakshmi Prabha Subhash, Professor and Head, Department of Anatomy, SSMC, Tumkur, Karnataka, India for her constant support and guidance in doing the research work.

REFERENCES

- [1] Williams PL, Banister LH, Berry MM, Collins P, Dyson M, Dussek JE, et al. editors. *Neurology*. In: *Gray's anatomy*. 38th ed. London: Churchill Livingstone; 1995. Pp. 870,1258-74.
- [2] Snell, RS. *Clinical Anatomy* 9th edition. Chapter- lower limb, femoral nerve. Lippincott Williams and Wilkins 2012: Pp.463.
- [3] Newell RLM, Pelvicgirdel, gluteal region & hipjoint. In: *Gray's anatomy-The anatomical basis of clinical practice*. S Satanding, H Ellis, JC Healy, D Jhonson, A Williams, Eds.; 39th Edn.; Elsevier Churchill Livingstone, Philadelphia, 2005; Pp.1455.
- [4] Drake RL, Vogl AW, Mitchell AWM. *Gray's Anatomy for Student's 2nd edition*. Chapter-lower limb, femoral nerve. Churchill Livingstone Elsevier Canada, Philadelphia, 2010: page 537-38.
- [5] Eisler P. Des Plexus lumbosacral des Menschen. *Anat Anz*. 1891;6:274.
- [6] Romanes GJ. *Cunningham's textbook of anatomy*, 12th edition. Peripheral nervous system (femoral nerve). Oxford, New York, Toronto: Oxford University Press; 1995:794-95.
- [7] Boezaart AP. Lumbar vertebral (psoas compartment) block. *The Journal of the New York School of Regional Anaesthesia*. 2006;11:55-62.
- [8] Ellis H, Feldman SA, Harrop Griffith W. *Anatomy for Anaesthetists*. 8th Edn.; Massachusetts: Blackwell Publishing; 2004; Pp.188-91.
- [9] Ravindranath Y, Manjunath KY, Ravindranath R. Accessory origin of the Piriformis muscle. *Singapore Med J*. 2008;49(8):217.
- [10] Spratt JD, Logan BM, Abrahams PH. Variant slips of psoas and iliacus muscles, with splitting of the femoral nerve. *Clin Anat*. 1996;9(6):401-04.
- [11] Vazquez MT, Murillo J, Maranillo E, Parkin IG, Sanudo J. Femoral nerve entrapment: A new insight. *Clinical Anatomy*. 2007;20(2):175-79.
- [12] Anloague PA, Huijbregts P. Anatomical variations of the lumbar plexus: a descriptive anatomy study with proposed clinical implications. *Journal of Manual and Manipulative Therapy*. 2009;17(4):e107-14.
- [13] Romanes GJ. The posterior abdominal wall nerves. In: *The abdomen*. In: *Cunningham's manual of practical anatomy Vol II*. 15th ed. New York: Oxford University Press; 1996. Pp. 181-82.
- [14] Thieme Frederick P. *Lumbar Breakdown Caused by Erect Posture in Man*. United States: University of Michigan Press, 1950. Pp.1-4
- [15] Izci Y, Gurkanlar D, Ozan H, Gonul E. The morphological aspects of lumbar plexus and roots an anatomical study. *Turkish Neurosurgery*. 2005;15(2):87-92.
- [16] Matejckik V. Anatomical variations of lumbosacral plexus. *Surg Radiol Anat*. 2010;32:409-14.
- [17] Bardeen CR, Elting AW. A stastical study of the Variations in the formation and position of the lumbo-sacral plexus in man. *Anat Anz*. 1901;19:124-209.
- [18] Astik RB, Dave UH. Variations in formulation and branching pattern of the femoral nerve in iliac fossa: A study in 64 Human Lumbar plexuses. *People's Journal of Scientific Research*. 2011;4(2):14-19.
- [19] Bergman RA, Afifi AK, Miyauchi R. Lumbar plexus. In: *Nervous system plexuses*. In: *Illustrated encyclopaedia of human anatomic variations part III* [online] 2006 [cited 2009 nov10]; [2 screens]. Available from: URL: [http://www.anatomyatlases.org/AnatomicVariants/NervousSystem/Text/Lumbar plexus.shtml](http://www.anatomyatlases.org/AnatomicVariants/NervousSystem/Text/Lumbar%20plexus.shtml).
- [20] Galzio R, Lucantoni D, Zenobii M, Cristuib-Grizzi L, Gadaleta A, Caffagni E. Femoral neuropathy caused by iliacus hematoma. *Surgical Neurology*. 1983;20(3):254-57.
- [21] Warfel BS, Marini SG, Lachmann EA, Nagler W. Delayed femoral nerve palsy following femoral vessel catheterization. *Archives of Physical Medicine and Rehabilitation*. 1993;74(11):1211-15.
- [22] Sharrock N. Inadvertent "3-in-1" block following injection of the lateral cutaneous nerve of thigh. *Anaesthesia and Analgesia*. 1980;59(11):887-88.
- [23] Morgan EG, Mikhail MS, Murray MJ. *Peripheral nerve blocks*. In: *Clinical Anaesthesiology*. 3rd ed. USA: McGraw Hill Publications; 2000. Pp. 298-307,352-54.
- [24] Benglis DM, Vanni S, Levi AD. An anatomical study of the lumbosacral plexus as related to the minimally invasive transpsoas approach to the lumbar spine. *J Neurosurg Spine*. 2009;10:139-44.
- [25] Cardosi RJ, Cox CS, Hoffman MS. Postoperative neuropathies after major pelvic surgery. *Obstetrics & Gynecology*. 2002;100(2):240-44.
- [26] Hollis NH, Lemay DE, Jensen RP. Nerve entrapment syndromes of the lower extremity [online] 2010 [cited 2011 Sep 10]; [5 screens]. Available from: URL: <http://www.med.nyu.edu/neurosurgery/pns/conditions/injuries/obturators.shtml>.
- [27] Moore AE, Stringer MD. Iatrogenic femoral nerve injury a systematic review. *Surg Radiol Anat*. 2011;34:55-58.
- [28] Al-Ajmi A, Rousseff RT, Khuraibet AJ. Iatrogenic femoral neuropathy two cases and literature update. *J Clin Neuromuscul Dis*. 2010;12(2):66-75.
- [29] Dillavou ED, Anderson LR, Bernert RA, Mularski RA, Hunter GC, Fiser SM, et al. Lower extremity iatrogenic nerve injury due to compression during intraabdominal surgery. *Am J Surg*. 1997;173(6):504-08.
- [30] Das S, Vasudeva N. Anomalous higher branching pattern of the femoral nerve a case report with clinical implications. *Acta Medica*. 2007;50(4):245-46.
- [31] Rao TR, Vanishree, Kanyan PS, Rao S. Bilateral variation of iliacus muscle and splitting of femoral nerve. *Neuroanatomy*. 2008;7:72-75.
- [32] Cunningham DJ. *Textbook of Anatomy*. 2nd Edn.; William Woodand Company, NewYork, 1905; pp. 662-73.

PARTICULARS OF CONTRIBUTORS:

1. Associate Professor, Department of Anatomy, Sri Siddhartha Institute of Medical Sciences and Research Centre, Bangalore Rural, Karnataka, India.
2. Associate Professor, Department of Anatomy, Sri Siddhartha Institute of Medical Sciences and Research Centre, Bangalore Rural, Karnataka, India.
3. Tutor, Department of Anatomy, Sri Siddhartha Institute of Medical Sciences and Research Centre, Bangalore Rural, Karnataka, India.
4. Senior Resident, Department of Orthopaedics, Sri Siddhartha Medical College, Tumkur, Karnataka, India.
5. Professor and Head, Department of Anatomy, Sri Siddhartha Institute of Medical Sciences and Research Centre, Bangalore Rural, Karnataka, India.

NAME, ADDRESS, E-MAIL ID OF THE CORRESPONDING AUTHOR:

Dr. BJ Archana,
Associate Professor, Department of Anatomy, Ground Floor, Sri Siddhartha Institute of Medical Sciences and Research Centre, T Begur, Nelamangala, Taluk Bangalore Rural-562123, Karnataka, India.
E-mail: drarchanabelavadi@gmail.com

AUTHOR DECLARATION:

- Financial or Other Competing Interests: None
- Was Ethics Committee Approval obtained for this study? No
- Was informed consent obtained from the subjects involved in the study? No
- For any images presented appropriate consent has been obtained from the subjects. No

PLAGIARISM CHECKING METHODS: [Jain H et al.]

- Plagiarism X-checker: Oct 08, 2020
 - Manual Googling: Nov 23, 2020
 - iThenticate Software: Jan 05, 2021 (24%)
- This is excluding the methodology of another published paper by the same author.

ETYMOLOGY: Author Origin

Date of Submission: **Oct 07, 2020**
Date of Peer Review: **Oct 22, 2020**
Date of Acceptance: **Nov 24, 2020**
Date of Publishing: **Apr 01, 2021**